

UNIVERSITA' DEGLI STUDI DI CATANIA

FACOLTA' DI MEDICINA E CHIRURGIA

**DOTTORATO DI RICERCA IN PROBLEMATICHE IN CHIRURGIA
GERIATRICA, ADDOMINALE TORACICA E D'URGENZA**

XXIV CICLO

Dott.ssa Simona Scapellato

***ACUTE MESENTERIC ISCHEMIA,
OCCLUSIVE AND NONOCCLUSIVE CAUSES IN
ELDERLY***

—————
TESI DI DOTTORATO
—————

Coordinatore:

Chiar.mo Prof. G. Basile

Tutor:

Chiar.mo Prof. G. Basile

TRIENNO 2009 - 2011

*A mia madre, donna accorta, onesta e tenace,
ed a tutta la mia meravigliosa famiglia per
il supporto e la collaborazione manifestatemi
sempre durante gli studi e l'attività lavorativa.*

INDEX

INTRODUCTION	4
PATHOPHYSIOLOGY	6
DIAGNOSIS	11
TREATMENT	21
OUR EXPERIENCE	31
CONCLUSION	44
REFERENCES	46

INTRODUCTION

Acute mesenteric ischemia is due to the sudden reduction of intestinal perfusion. It has been classified in acute mesenteric arterial embolus and thrombus, mesenteric venous thrombus and nonocclusive mesenteric ischemia. The acute arterial thrombosis accounts for 25% to 30% of cases ^{1,2} usually is a complication of underlying atherosclerosis, or, less frequently, of arteritis, fibromuscular dysplasia, dissection, trauma, or mesenteric aneurysm rupture ^{3,4}. Arterial embolism is the most common pathophysiology of acute mesenteric ischemia, accounting for 40% to 50% of cases ¹. Most embolic events are thromboembolic in nature and usually arise from a cardiac events. The embolus originates from the left ventricle, from the left atrium, or less frequently, from the thoracic or upper abdominal aorta ⁵⁻⁸.

The mesenteric vein thrombosis is, instead, the least common cause and frequently most cases have been classified as idiopathic.

Nonocclusive mesenteric ischemia is a result of hypoperfusion caused by a low cardiac output or mesenteric arterial spasm ⁹⁻¹¹.

The mesenteric ischemia is a potentially fatal vascular emergency with overall mortality rate of 70% ^{4,7,8,12-36} and its reported incidence is increasing (Table 1). It has been increasing due to longer mean life expectancy ³⁷ and the prevalence among 65-year-old subjects is approximately 20% ³⁸. The mortality is so high because of the difficulty in recognizing the proper diagnosis. Variable

presentations, misdiagnosed, and non specific clinical and laboratory findings delay the individuation of this condition and most of the patients are treated more than 24 hours after the onset of the symptoms ³⁶. There are no guidelines for its diagnosis and treatment based on the evidence of randomized controlled trials ³⁹.

Table 1.

FIRST AUTHOR	PUBBLICATION YEAR	NUMBER OF PATIENTS	MORTALITY RATE
Ottinger	1967	136	92%
Singh	1975	32	81%
Smith	1976	23	91%
Boley	1977	30	46%
Kairaluoma	1977	44	70%
Krausz	1978	40	78%
Sachs	1982	30	77%
Andersson	1984	60	82%
Lazaro	1986	23	27%
Wilson	1987	102	92%
Sitges-Serra	1988	83	71%
Finucane	1989	32	69%
Bapat	1990	20	40%
Batellier	1990	65	51%
Levy	1990	62	40%
Deehan	1995	43	70%
Ward	1995	34	45%
Konturek	1996	28	96%
Voltolini	1996	47	72%
Klempnauer	1997	90	66%
Urayama	1998	34	35%
Newman	1998	98	60%
Mamode	1999	57	81%
Foley	2000	21	24%
Woosup	2001	58	41%
Edwards	2003	76	62%
Wyers	2007	13	53%
Kassahun	2008	60	60%

PATHOPHYSIOLOGY

ARTERIAL EMBOLISM

Arterial embolism is the most common cause and nearly one third of all patients with a superior mesenteric artery embolus have a history of an antecedent embolic event ⁴⁰. Myocardial ischemia or infarction, atrial tachyarrhythmias, endocarditis, cardiomyopathies, ventricular aneurysms, and valvular disorders are all risk factors of intracardiac thrombus development. Actually the overall incidence of thromboembolism is in part declining with better guidelines for and compliance with anticoagulation in patients with atrial fibrillation ⁴¹.

In 70% of the intestinal vascular occlusion the superior mesenteric artery is involved ⁴² in fact it receives an embolus more commonly than the celiac trunk because of its oblique origin from the visceral aortic segment. Specifically, most emboli tend to lodge in the superior mesenteric artery distal to the origin of the middle colic artery, that is its first major branch ^{5,43}. This condition creates a classic pattern of ischemia that spares the first portion of the small bowel and the right colon.

Symptoms onset is usually dramatic and sudden as a result of the poorly developed collateral circulation. The history of a severe pain often is in contrast to the physical examination in which the abdomen is still soft and shows only discrete tenderness on palpation. The abdominal pain is generally localized periumbilically or in the right umbilical side.

The ischemic diagnosis due to embolism usually can be intraoperatively based on the distribution of the ischemic bowel, often the proximal jejunum is spared, whereas the rest of the small bowel is ischemic or infarcted.

ARTERIAL THROMBOSIS

Arterial thrombosis is quite common in fact it's due to a pre-existing stenosing atherosclerosis of visceral arteries, and the most common site is near the origin of the superior mesenteric artery. There are autopsy studies in which the incidence of > 50% stenosis in at least one mesenteric artery occurs in 6% to 10% of the population ⁴⁴. Thrombotic occlusions are localized more proximally than embolic occlusions, intestinal infarction is usually more extensive and thrombotic occlusions are associated with old brain infarction, aortic wall thrombosis, and disseminated cancer. Thrombosis or severe atherosclerotic changes of the celiac trunk are present in 33% of those with thrombosis in the superior mesenteric artery ⁴⁵. Approximately 50% to 75% of patients presenting this condition have had prior symptoms compatible with chronic mesenteric ischemia ⁴⁰, like postprandial abdominal pain, food avoidance and weight loss. They may have a more insidious onset of disease since pre-existing atherosclerosis usually leads to the development of collaterals that are able to maintain viability until there is a final closure of a critically stenotic vessel or collateral. The extent of bowel ischemia or infarction is typically greater than with embolism, extending from the duodenum to the transverse colon. Perioperative mortality ranges to 70% to 100% ^{2,10,20} in part

because of the delay in diagnosis, the extensive nature of the bowel ischemia infarction, and the need for more complex surgical revascularization.

VEIN THROMBOSIS

Mesenteric vein thrombosis is a rare form of the intestinal ischemia, representing 10% to 15% of patients^{1,10}. Hemorrhagic infarction occurs when the intramural vessels are occluded. The superior mesenteric vein is most often affected, with involvement of the inferior mesenteric vein and the large bowel being uncommon. It may insidiously evolve and may remain asymptomatic for weeks or months, but may also present as an acute severe disease. There are some mesenteric vein thrombosis predisposing factors, like all states of hypercoagulability, portal hypertension, portal vein thrombosis, abdominal inflammations and a history of previous surgery or abdominal trauma. The clinical presentation includes abdominal pain with a wide range of intensity, duration and localization. More than 50% of patients complain about nausea and vomiting. Bloody diarrhoea, hematochezia and hematemesis indicate that mesenteric infarction has already occurred.

In most cases abdominal pain has already been present for some days before admission in hospital, actually a subacute development of mesenteric vein thrombosis, abdominal discomfort may be present for weeks or even months without evidence of manifest mesenteric infarction. The mortality in patients with acute mesenteric vein thrombosis is around 60%-70% whereas patients with the chronic form of the disease have a mortality of 20%⁴⁶.

NONOCCLUSIVE MESENTERIC ISCHEMIA

Approximately 20% of patients with mesenteric ischemia have nonocclusive disease^{47,48}. Its pathogenesis is poorly understood but it is the result of a seriously diminished blood supply of the intestine caused by a low cardiac output state associated with diffuse mesenteric vasoconstriction. Splanchnic vasoconstriction in response to hypovolemia, decreased cardiac output, hypotension, or vasopressors best explains the difference between this entity and other forms of acute mesenteric ischemia. Patients with an open but stenotic superior mesenteric artery are older than those without a stenosis and they have more often a concomitant stenosis of the celiac trunk⁴⁹. Conditions predisposing include myocardial infarction, congestive heart failure, aortic insufficiency, cardiopulmonary bypass, renal or hepatic disease, and major abdominal or cardiovascular surgery. Drugs with an effect on splanchnic perfusion have been incriminated as a cause for nonocclusive mesenteric ischemia, for example the digitalis preparations induce contraction of splanchnic venous and arterial vascular smooth muscle⁵⁰. Other drugs that potentially decrease mesenteric blood flow include catecholamines, ergotamine, angiotensin II, vasopressin and beta-blockers⁵¹. Even cocaine abuse is described causing mesenteric ischemia⁵². However, patients may not have any clear risk factors^{48,53} since often they are critically ill and with considerable comorbidities, the onset may be insidious and the mortality rates are high. An unusual form of nonocclusive ischemia, with an incidence of 0.3% to 8.5%, has been described in patients who undergo the stress

of a surgical procedure or trauma and receive enteral nutrition in intensive care units ⁵⁴. Their survival is poor, around 56% ⁵⁵.

Nonocclusive mesenteric ischemia may be very difficult to distinguish from thromboembolic occlusion of the superior mesenteric artery without mesenteric angiography or autopsy because these conditions have common risk factors ⁴⁵.

DIAGNOSIS

CLINICAL PRESENTATION

Many of the signs and symptoms of acute mesenteric ischemia are easily mistaken for other more common intra-abdominal pathologies, like pancreatitis, appendicitis, cholecystitis, acute diverticulitis and small bowel obstruction. The intensity of symptomatology during the presentation of the disease depends of the degree of transmural involvement of the bowel. Initially, the ischemia secondary to a reduced blood flow can be tolerate without permanent remarkable cellular damage. It is due to a mechanism that include direct arteriolar smooth muscle relaxation and a metabolic response to adenosine and other metabolites of mucosal ischemia ⁵⁶. Instead prolonged ischemia leads to disruption of the intestinal mucosal barrier with a cohort of increasing symptoms.

When ischemia is due to an embolus the onset of symptoms is usually dramatic because of lack of collateral circulation and it manifests as sudden and severe abdominal pain out of proportion to the physical findings. However it should be supposed in patients older than 50 years with congestive heart failure, cardiac arrhythmias, recent myocardial infarction, hypovolemia, hypotension or sepsis ⁵⁷. Dehydration and excessive fluid loss of third spacing lead to mental confusion, tachycardia, tachypnea, and circulatory collapse.

Except in the most fulminant cases, patients with arterial thrombosis report a prodromal symptom complex of post-prandial pain, nausea, anorexia and weight

loss associated with chronic intestinal insufficiency^{45,58}. Usually it involves elderly patients, in a study mesenteric arterial disease was found in 18% of patients aged over 65 years and 70% of those undergoing aortobifemoral bypass^{10,38}. Moreover they may have a history of deep vein thrombosis⁵⁷.

Patients with mesenteric venous ischemia usually present late, diffuse and unspecific abdominal pain, with diarrhoea and anorexia. Compared with arterial thrombosis the venous form generates fewer prodromal symptoms during the meal or postprandial like fever, abdominal distension and hemocult-positive stool samples.

Nonocclusive mesenteric ischemia occurs most frequently in critically ill elderly, often intubated and sedated, unable, therefore, to alert the clinician of the symptoms. In these circumstances, the intestinal ischemia may not become clinically evident until hours or days after the initial hemodynamic insult.

Gastrointestinal symptoms may be unspecific and present as constipation, loss of appetite, nausea, vomiting and discontinuous abdominal pain. Diarrhoea with blood, mucus and melena may ensue.

Independently from the pathophysiology, when infarction occurs the patients start to present peritoneal signs and hemodynamic instability until to signs of sepsis and in the final step of multiorgan failure.

LABORATORY EVALUATION

Laboratory studies are nonspecific, with the most common laboratory abnormalities being hemoconcentration, leucocytosis and an anion gap acidosis.

High levels of serum lactate, C-reactive protein, amylase, aspartate aminotransferase, lactate dehydrogenase and creatine phosphokinase can also be observed but all of the serum markers are completely insensitive and nonspecific for the diagnosis of mesenteric ischemia ⁵⁹⁻⁶³. Hyperkalemia and hyperphosphatemia usually are late signs and frequently are associated with bowel infarction ⁶⁴.

Promising data have been showed using a low serum D-dimer levels (a fibrinolytic marker of acute vascular events) as an exclusionary test for acute mesenteric ischemia ⁶⁵⁻⁶⁷. The sensitivity and specificity of the postprandial elevation of D-dimer are both 63% ⁶⁸.

We are still far away from having specific and sensitive serum markers like in myocardial ischemia. Some studies are looking for a future blood test for acute mesenteric ischemia, it's an enzyme immunoassay for elevated levels of intestinal fatty acid binding protein ^{61,69}.

DIAGNOSTIC IMAGING

Plain Abdominal Radiograph

The findings on abdominal plain films are also nonspecific. The most important reason for performing a plain abdominal radiograph is to exclude other acute abdominal diseases, in fact in 25% of cases patients may have normal findings ⁷⁰ or nonspecific like intestinal dilatation, gasless abdomen, a small-bowel pseudo-obstruction pattern. Characteristic radiograph abnormalities, such as thumbprinting or thickening of bowel loops, occur in less than 40% of patients at

presentation ⁵⁵. Highly suggestive, but rather uncommon and usually late signs include pneumatosis intestinalis, pneumoperitonuem or portal vein pneumatosis, they are late findings and associated with a poor prognosis ⁷⁰.

Ultrasonography

Ultrasonography is widely used as first diagnostic procedure in patients with acute abdominal pain. It may reveal a thickening of bowel walls, signs of ileus or subileus with distended bowel loops and hypoperistaltis ¹. Duplex ultrasonography can visualize the superior mesenteric artery in 80-90% in experienced hands ⁷¹. This study can visualize stenoses or occlusions in the celiac or superior mesenteric arteries. However it is often technically limited by distended, air filled bowel loops. Ultrasonography is the noninvasive diagnostic study of choice in patients with symptoms suggesting chronic mesenteric ischemia, but has little to no role in the diagnosis of acute mesenteric ischemia for several important reasons. It is highly user-dependent and many hospitals off hours don't have access to such test. Its sensitivity is very limited in the setting of more distal emboli or in assessing nonocclusive mesenteric ischemia. For all these reasons ultrasonography is classified as non-standard diagnostic test and its use for acute mesenteric ischemia is rather discouraged ⁷².

Computed Tomography

Computed tomography is used more and more frequently, even in small hospitals and its technology is rapidly increasing. CT is usually used as one of the first imaging techniques in patients with abdominal pain. This study describes

nonspecific signs such as thickened bowel walls, intramural hematoma, dilated fluid-filled bowel loops, mesenteric oedema, ascites, pneumatosis, engorgement of mesenteric vessels, mesenteric or portal venous gas, infarction of other viscera. The presence of intestinalis pneumatosis on computed tomography does not necessarily indicate the presence of transmural infarction, however transmural infarction is more common in patients with pneumatosis and porto-mesenteric venous gas ⁷³. Abdominal CT scanning in general has poor sensitivity and also a low specificity (around 39%) ⁷⁰ in the diagnosis of most types of acute mesenteric ischemia. It may be helpful in excluding other pathologies. Computed tomography may demonstrate venous obstruction better than other types of acute mesenteric ischemia, in fact it usually shows the thrombus in mesenteric vein and also in portal or splenic vein when thrombosis interests these districts. Its sensitive for mesenteric vein thrombosis lies between 90% and 100% ⁷⁴⁻⁷⁶, for this reason CT is the investigation test of choice in suspected cases of mesenteric venous thrombosis ^{74,77,78}.

Multislice technology has recently been introduced for CT angiography, and this may further improve the CT results in acute mesenteric ischemia ⁷⁹. CT angiography is an accurate way to image the splanchnic arteries, veins and collaterals ⁸⁰⁻⁸³. It is essential to use multi-slice scanners with slice thicknesses of 2 mm at most (preferably 1 mm) to allow accurate visualization of the arteries. CT angiographic visualization is judged to be satisfactory in all cases up to second order branches of both the celiac and superior mesenteric artery ⁸⁴. This imaging

diagnostic test can be seriously considered a competitor for conventional angiography ^{79,81,85,86}, if we consider that it shows abdominal vascular tree and therefore bowel perfusion but also other viscera since to offer the ability to exclude other causes of abdominal pain. In addition it presents the advantages of minimal invasiveness and lower costs. Some authors are able to achieve a positive and negative predictive value of 100% and 96% respectively using a combination of CT criteria to generate an overall impression ⁸⁷.

Magnetic Resonance Angiography

Magnetic resonance angiography is promising diagnostic modality and may be more useful than conventional CT scans because they provide high-resolution functional images indicating low oxygen saturation ⁸⁸ but the secondary signs of acute mesenteric ischemia, such as indurated fat or bowel wall thickening, which are routinely delineated by multislice CT, are more difficult to assess with MR ⁸⁴. It is noninvasive, avoids the risk of allergic reaction and nephrotoxicity associated with iodinated contrast agents, and may not be operator-dependent. Magnetic resonance angiography evaluation of the mesenteric arteries is primary limited to the proximal celiac and superior mesenteric artery and it does not currently provide sufficient resolution to demonstrate distal emboli ⁸⁹. Several studies suggest that magnetic resonance angiography may be highly sensitive for diagnosing mesenteric vein thrombosis ^{90,91}.

Angiography

In the absence of clinical signs, such as peritonitis, that need emergent laparotomy, mesenteric angiography remains the gold standard of investigations when acute mesenteric ischemia is suspected ^{10,43,92,93}. Although routine angiography decreases the mortality rate without an apparent increase in complications in many series ^{73,92,94-97} the role of preoperative angiography is still controversial in patients suspected of having acute mesenteric ischemia and peritoneal signs. Angiography must be biplanar ⁹⁸. Visceral angiography involves three steps: 1) a non-selective anterior-posterior abdominal aortic angiography, it is the best view for visualizing the distal mesenteric vasculature ; 2) a lateral aortography during maximal inspiration and expiration for visualizing the origins of the major visceral arteries; 3) selective angiography of all three splanchnic vessels to obtain a detailed view of the vascular anatomy, stenoses and anatomical variations ⁹⁹. Mesenteric angiography usually can differentiate embolic from thrombotic occlusions by the nature of the filling defect patterns, may establish the exact localization of the obstruction and it may give valuable information for treatment. A mesenteric artery embolus presents as sharp, rounded filling defect in the contrast column with a typical menisc sign. These emboli are usually located at vessel narrowings, major branch vessel origins or bifurcations, not often just distal to the middle colic artery origin ^{92,100}. Thrombotic occlusion of the superior mesenteric artery shows a sudden cut-off of the contrast generally at the vessel origin or within 1-2 cm of the superior mesenteric artery trunk ^{92,100}. Diagnosis is supported by atherosclerosis in other vessels. If an embolus lodges at the superior

mesenteric artery origin, differentiation from thrombosis may be difficult. Mesenteric venous thrombosis is characterized by a generalized slowing and vasoconstriction of the arterial flow in conjunction with lack of opacification of the corresponding mesenteric or portal venous outflow tracts. This is frequently segmental, in contrast to nonocclusive mesenteric ischemia, which is diffuse and shows normal venous runoff⁴⁰. For nonocclusive mesenteric ischemia, angiography remains the only reliable diagnostic tool that should be applied early in the diagnostic process. Angiographic criteria for this form of intestinal ischemia include a diffuse narrowing of the mesenteric superior artery and its branches, alternating areas of narrowing and dilatation of the major superior mesenteric ischemia branches (called the "string of sausages" sign) and spasm of the peripheral vascular arcades^{100,101}.

Angiography of the splanchnic vessels can be used to perform endovascular therapeutic procedures in the same session. With an ever-expanding list of endovascular treatments or adjuncts, its therapeutic role is strengthened. It still offers several treatment options, including injection of intraarterial vasodilators such as papaverine¹⁰², thrombolysis¹⁰³, and angioplasty with or without stenting of stenoses¹⁰⁴. In acute splanchnic infarction, angiography serves as guideline for endovascular or operative revascularization. The confirmatory diagnostic arteriogram can be accomplished in the operating room followed by immediate surgical exploration. This coupling of angiography with definitive surgical treatment could save precious time in the treatment of these challenging patients.

It's preferable to perform this procedure under general anaesthesia for several reasons that are a) procedures can be long and sometimes painful for the patients; b) the ability to lay still and holding their breath are keys to adjust imaging and treatment; c) if a laparotomy is needed the patient is prepared and already in operating room ¹⁰⁵. Many vascular centres have dedicated hybrid operating rooms with high-quality, fixed angiographic systems. The technique include a femoral or, less frequently, brachial access. As in all instances of endovascular interventions, especially if thrombolytic therapy is being considered, accurate puncture technique cannot be overemphasized. A brachial access is reserved, typically, for very sharp vessels and also, in cases where a proximal stenotic lesion is an underlying cause of a thrombotic occlusion because a brachial access allows to have a better angle of access and perhaps less risk of dissection during stenting. The choice of access must be valued carefully in each situation to optimize the treatment. To help the visualization of mesenteric vasculature the patient is given glucagone intravenously to cease bowel movements.

Other diagnostic modalities

Experimental studies showed that acute mesenteric ischemia causes a dramatic decrease in liver blood flow ¹⁰⁶⁻¹⁰⁸. Reduction of portal blood flow is associated with a decrease of portal pressure and results in a decrease of the hepatic blood volume ¹⁰⁹. Both hepatic blood flow and blood content can be measured non invasively by PET ^{110,111}. The liver receives blood supply by 75% portal vein and 25% hepatic artery. In low flow states, such as cardiogenic shock

or haemorrhage, a decrease in hepatic perfusion is caused by reduction of flow in both vessels. In contrast, acute mesenteric ischemia leads to reduction only of portal flow. There is need for a non invasive imaging method capable of early diagnosis of acute mesenteric ischemia and there is in literature a study showing that PET imaging of liver circulation can recognize acute mesenteric ischemia ¹¹². It is also capable of identifying compromised liver circulation during reperfusion of ischemic intestine so Pet could be used both in the diagnosis of acute mesenteric ischemia and in the follow-up after revascularization.

Diagnostic laparoscopy has limited ability to assess bowel viability in fact serosal colour sometimes can be difficult to judge and can be distorted significantly, moreover segmental ischemia can be missed because of the difficulty in observation of the bowel along its entire length and over all surfaces. Generally, diagnostic laparoscopy for this indication has not been widely accepted ¹¹³, but it may be useful for investigating acute mesenteric ischemia due to venous thrombosis, actually serosanguineous fluid in the abdominal cavity of an older patient with abdominal pain, haemoconcentration, and leukocytosis is strongly suggestive of mesenteric venous thrombosis ¹¹⁴.

TREATMENT

Acute mesenteric ischemia treatment can be categorized into four key principles: prevention; early diagnosis and rapid treatment; proper intraoperative decision making; aggressive postoperative management.

PREVENTION

For the prevention we have to recognize, in many cases of mesenteric artery thrombosis, prodromic symptoms that are expression of chronic mesenteric ischemia. It is necessary to hypothesize a chronic mesenteric ischemia, prelude of acute ischemia, when someone has recurrent postprandial pain, after 15-30 minutes after a meal and persisting for 1-3 hours. Patients often present fear of eating, and take smaller meals. Weight loss, caused by reduced intake and not to malabsorption, is the second characteristic finding in these patients.

In case of mesenteric artery embolism 33% to 75% of patients have a history of atrial fibrillation and are not on anticoagulants ^{33,34}. It is need to give anticoagulants to patients with cardiac abnormalities such as cardiac arrhythmias, cardiac valve disease or coronary heart disease and, of course, previous arterial or cerebral embolisms.

A mesenteric venous thrombosis prevention is not easy, but when there are states of hypercoagulability, recent major surgery or abdominal trauma or tumours is appropriate to use anticoagulants.

It's required to maintain high attention about ill patients in intensive care units such as when abdominal tenderness gradually makes worse and nausea, diarrhoea, bleeding emerge, expressions of intestinal ischemia, the treatment may be rapid and efficacy before full thickness necrosis of bowel wall becomes irreversible.

EARLY DAGNOSIS AND TREATMENT

When acute mesenteric ischemia diagnosis is suspected, the stable patient without peritoneal signs should proceed to non-invasive or/and invasive imaging diagnostic tests without delay. Once the diagnosis is checked in combination to the revascularization it's indispensable to start active aggressive rehydration and treatment of underlying condition. The administration of fluids and electrolytes is aimed at replacing fluid lost intraluminally. It often is required large amounts of intravenous fluids. Standard dosage for lactated Ringer's solution is up to 100 ml/kg. It is very effective, another advantage is that it is cheap. Contraindications include cardiac insufficiency and pulmonary oedema. Because of the large and ongoing fluid sequestration in these patients serial examination and bladder pressure monitoring are to recommend such that it's possible to recognize the development of abdominal compartment syndrome.

Vasopressors are used in the setting of systemic hypotension. Dopamine is used in low doses (5 µg/kg per minute intravenously). It is moderate in costs and very effective. Its main side effects are hypertension, tachyarrhythmia, nausea, vomiting, headache, ipoK. Contraindications include hypersensitivity,

pheochromocytoma, tachyarrhythmia, severe aortic stenosis whereas its main drug interaction is alkaloid solutions . Dobutamine is useful in case of decreased cardiac output. Its standard dosage initially is 1 µg/kg per minute intravenously while maintenance dosage is variable from 2.5 to 10 µg/kg per minute intravenously. Also this vasopressor is moderate in costs and very cost effective. Main side effects include hypertension, tachyarrhythmia, angor, hypokalemia, nausea, headache, asthma, and rarely eosinophilia and thrombocytopenia. Contraindications include hypersensitivity, idiopathic hypertrophic cardiopathy, severe aortic stenosis, tachyarrhythmias, hypovolemia, pheochromocytoma. Never give this vasopressor with alkaloid solutions. Its main drug interactions is isocarboxazid.

Vasodilators dilate the mesenteric arterial system reversing reactive arterial vasospasm in acute mesenteric ischemia. Papaverine usually is administered intravenously via selective angiography catheter with a standard dosage of 30-60 mg/h, but its cost is high. The main side effects are hypertension, tachyarrhythmia, hepatotoxicity, itch, rash, nausea, vomiting, headache, asthenia, and priapism. Contraindications include hypersensitivity and complete atrioventricular block. It should be used with caution in patients with glaucoma or recent myocardial infarction and stroke. It precipitate when administered together with heparin. It's to be avoided its administration in contemporary with beta-blockers and levodopa .

Once the diagnosis of acute mesenteric ischemia is made revascularization is necessary. It can be achieved using endovascular technique. This therapy offers

the advantages of intervention at the time of angiographic diagnosis. It's possible to obtain the revascularization by the administration of anticoagulants or thrombolytic agents and/or vasodilators. Especially in case of mesenteric venous thrombosis, in the absence of peritoneal signs, anticoagulant therapy should be started immediately. Patients are first treated with heparin for 7-10 days and then an oral regimen of anticoagulants for 3-6 months. Thrombolytic therapy is most likely to be successful if treatment is started within 12 hours of the onset of symptoms. It's opportune to control catheter position and thrombolytic effects using angiography every 12 hours or, otherwise, depending on the clinical status of the patient. This technique presents some disadvantages, there is often not enough time in patients with acute mesenteric ischemia to use lysis as a sole treatment and there is the risk of fatal gastrointestinal bleeding if underlying bowel necrosis exists ¹⁰⁵. Besides exploratory laparotomy will preclude the use of thrombolytics. Lysis is reserved mainly for patients with suspicion of initial bowel ischemia or only mucosa ischemia or in conjunction with mechanical clot removal to achieve a faster clot clearance ¹¹⁵. The aspiration of superior mesenteric embolus requests a brachial or femoral approach. With the wire in place (typically a 7 Fr) 45 cm introducer with removable hub is placed proximal to the embolus. Inside this, a 4 to 6Fr guiding catheter is introduced into the clot and aspiration with a 20 mL syringe is applied manually to the guide simultaneous with sheath withdrawal ¹⁰⁵. This technique presents a risk of vessels dissection because of the wire. Dilatation with standard 4- to 5-mm percutaneous transluminal angioplasty

balloons can then be performed after aspiration and/or thrombolysis. The occlusive lesion is then stented preferably with a balloon-expandable stent. It is important to choose not too small stent. In cases of more distal lesions self-expandable stents are used to better accommodate for superior mesenteric artery. The endovascular approach doesn't allow the inspection of the bowel at the time of the procedure. It is possible to perform it when the clinical status is not serious and in initial stage. An option is a hybrid approach employing an endovascular retrograde superior mesenteric artery access during laparotomy ¹¹⁶⁻¹¹⁸. Obviously, to perform this combined technique an angio-equipped operating room is indispensable.

If the superior mesenteric obstruction is determined by a fresh clot, the vessel is clamped distally to avoid distal embolization after the recanalization. The visceral peritoneum is incised preferably longitudinally at the base of the transverse mesocolon. A puncture is made in the vessel approximately 6 cm distal to the origin in the aorta. A local thrombo-endarterectomy is performed if necessary. Placing a patch (usually bovine pericardium) angioplasty then facilitates retrograde cannulation of the superior mesenteric artery. The patch can be further protected by closure of the peritoneum over the site of the superior mesenteric artery exploration. This technique during emergent laparotomy is promising and an attractive alternative to emergent surgical bypass, but it presents a high rate of recurrent stenosis ^{35, 119-122}. A superior mesenteric artery operative bypass is, certainly, more durable. In all cases the surgeon should proceed with revascularization before resecting any intestine. There are two variants in the

technique for the exposure of the superior mesenteric artery. It can be approached anteriorly at the base of the transverse mesocolon if an embolus is confirmed. Instead if the etiology is thrombotic a lateral approach of the artery above the fourth portion of the duodenum is preferred to facilitate a retrograde bypass. Its origin may be from the right common iliac artery (this avoids any aortic clamping) or from the left iliac or distal infrarenal aorta. Bypass may be also anterograde. The supraceliac aorta is often relatively free of disease and the more straight graft orientation is less prone to kinking. Dissection of this part of aorta, however requires more time and needs its clamping. The graft may be synthetic (Dacron or polytetrafluoroethylene) or natural (veins). The choice of conduit is influenced by the degree of abdominal contamination and then the risk of graft infection. Advantages for vein bypass are that it is autologous and is less prone to infection. Its disadvantages are that it takes additional time to harvest. It's not required further time for prosthetic graft bypass but it is prone to infection in a contaminated field and besides, it presents additional cost. Greater saphenous and thigh femoral vein are the primary options. When it is possible at least two mesenteric vessels would be revascularized to ensure complete visceral revascularization and protect against future ischemia¹²³. Only frankly necrotic intestine has to be resected at the initial operation. Before to decide how long bowel to remove it would wait for 20 to 30 minutes of reperfusion time. Some authors described in literature the use of fluorescein and a perfusion fluorometer or the use of a laser Doppler flowmeter^{124,125}.

PROPER INTRAOPERATIVE DECISION MAKING

Frequently, after reperfusion and careful assessment, bowel viability cannot frequently be determined with certainty at the time of the initial exploration. For this reason, a second-look surgery after 24 to 48 hours is usually recommended¹²⁶, later may be warranted¹²⁷. The decision to reoperate is made during the first operation and is independent of the clinical status of the patient during the initial procedures. Typically, at the conclusion of the initial procedure, the surgeon leaves transected ends of the bowel closed with stapler without re-anastomosis. At the time of the second look almost 50%^{33,34} of patients require additional resection of ischemic bowel that is progressed to fully-thickness necrosis. It's interesting to note that additional resection is more common required among patients with embolic obstructions³⁴. At re-exploration the viability of the bowel is usually defined, but occasionally a third look is required before final bowel anastomosis are performed. The additional intestinal resection is associated with improved survival rate and it's not associated with an increased risk of perioperative morbidity, mortality or postoperative total parental nutrition dependence. Second-look laparoscopy has been advocated as a substitute for second-look laparotomy, but the reliability of this approach remains unproved^{128,129}.

AGGRESSIVE POSTOPERATIVE MANAGEMENT

The postoperative management has the aim to avoid reperfusion injury, to prevent clot propagation and thwart septic complications. Postoperatively, patients treated for acute mesenteric ischemia are constantly critically ill. Multiorgan

failure is the most lethal complication and it is the result of a combination of different factors: bowel ischemia, hypoperfusion, liberation of free-radicals and sepsis. Adequate volume resuscitation is essential to avoid persistent mesenteric hypoperfusion. The mesenteric capillary leak syndrome after mesenteric revascularization is well recognized. Frequently, patients with this condition require to 10 to 20 litres of crystalloid resuscitation during the first 24 to 48 hours after surgery. Metabolic acidosis and hyperkalemia should be aggressively corrected. After successful revascularization, efforts should be directed toward limiting any reperfusion injury that may cause progressive mesenteric ischemia or infarction. If the patient's hemodynamic condition allows, infusions of vasodilators should be considered. As vasodilators it's possible to use intra-arterial papaverine or intravenous glucagon. The latter can be infused initially at 1 µg/kg per minute and titrated up to 10 µg/kg per minute as tolerated. Glucagon, furthermore, reduces the mesenteric vasospasm associated and hypertonicity with reperfusion therefore reduces oxygen demand. This drug presents high cost. Side effects include hyperglycemia, hypokalemia, rash, nausea, vomiting, and hypertension. Contraindications are hypersensitivity, known pheochromocytoma and use of warfarin. To reduce the reperfusion syndrome and to improve overall mortality it is useful introduce in therapy free-radical scavengers like allopurinol, angiotensin-converting enzyme inhibitors or other oxygen radical scavengers¹³⁰. Allopurinol dosage is 300 mg /dL intravenously for 24 to 48 hours. It is low in cost. Its main side effects are rash, nausea, vomiting, itch. Its alone contraindication is

hypersensitivity. And its main drugs interaction are enalapril and aziathioprine. Enalapril is the most common used angiotensin-converting enzyme inhibitors, the standard dosage is 1.25 mg intravenously every 6 hours. It's moderate in cost. The main side effects are hyperkalemia, nausea and vomiting. It's contraindicated in case of hypersensitivity and when it's known precedent angioedema. Drug interactions are allopurinol and aspirin.

To prevent clot propagation anticoagulants are necessary. When it's possible intravenously heparin should be administered to achieve an activated partial thromboplastin time of 50 to 70 seconds to reduce the chance of further progression of the arterial or venous thrombosis. The standard dosage is an initial bolus of 5000 UI then 1000 UI/h. It's low in cost and very effectiveness. Main side effects are bleeding and thrombocytopenia. Contraindications include hypersensitivity, active bleeding and severe thrombocytopenia. Drug interactions include digoxin, nicotine, tetracycline and antihistamines, all these elements decrease its effects while aspirin, dextran, dipyridamole and NSAIDs increase heparin's effect.

Broad-spectrum antibiotic therapy is used to protect against bacterial translocation from the ischemic bowel segment. Coverage should include gram-positive, gram-negative, and anaerobic bacteria. Levofloxacin used with metronidazole or with piperacillin/tazobactam are relatively inexpensive and very effective. Levofloxacin standard dosage is 500 mg intravenously every 24 hours. Side effects include nausea and diarrhoea, AST and ALT increasing.

Contraindications include hypersensitivity, epilepsy, prolonged QI interval and concomitant class IA or III antiarrhythmic, renal failure. Its main drug interactions are NSAIDs, warfarin, probenecid, cimetidine and steroids. The metronidazole standard dosage is 15 mg/kg administered intravenously. Main side effects include dyspepsia, diarrhoea, metallic taste, dry mouth and itch. The dose should be adjusted in hepatic disease. It may increase toxicity of anticoagulants, lithium and phenytoin, while cimetidine may increase metronidazole's toxicity. Standard dosage of piperacillin/tazobactam is 2.250 g intravenously every 6-8 hours. Its main side effects are rash, diarrhoea, nausea, vomiting, headache. Contraindication is hypersensitivity. Main drug interactions are probenecid, methotrexate and vecuronium.

Obviously, these patients, especially immediately after the operation, need to be carefully monitored and after the discharge their follow-up is necessary to prevent and to recognize quickly new intestinal ischemic episodes.

OUR EXPERIENCE

Patients treated at our Surgical Division of “Policlinic-Vittorio Emanuele” Hospital of the Catania’s University for acute mesenteric ischemia between January 2002 to November 2011 were forty-two. They presented acute mesenteric ischemia because of embolism, thrombosis and nonocclusive ischemia, while patients with mesenteric ischemia because of volvulus, adhesions, hernia or tumours were excluded. The clinic records of all these patients were retrospectively reviewed. The demographic information, comorbid conditions, history, physical examination findings, laboratory test results and records of the radiologic examination were abstracted. Moreover other data were recorded, such as post-operative complications, hospital stay and mortality. They are useful to try to establish if there are predictive factors to prevent this disease.

From this study in elderly three patients were excluded since they were younger than sixty-five year old.

They were 21 men (53.85%) and 18 women (46.15%) with mean age of 81.5 years (range 65 to 92 years). The cause of acute mesenteric ischemia was arterial embolism in 8 patients (20.51%), arterial thrombosis in 37 patients (69.23%), venous thrombosis in 1 patient (2.56%) and nonocclusive ischemia in 3 patients (7.70%). The patients with embolism, in comparison with the patients with thrombosis, were older and had a higher percentage of atrial fibrillation. Only one patient in embolism group was undergoing long-term anticoagulation therapy at

presentation. Atherosclerosis was highly prevalent and 49.15% of patients had disease in two or more vascular segments. Overall, clinically apparent heart disease (arrhythmias, coronary artery ischemia and/or congestive failure) was present in 43.59%, hypertension in 56.41%, diabetes mellitus in 30.77%, chronic renal insufficiency in 20.51%, anaemia in 12.82% and a history of tobacco use in 23.08%. Other medical comorbidities were chronic obstructive disease, cerebrovascular disease, hypercholesterolemia, chronic venous failure, hepatitis and tumours. Just thirteen patients didn't referred in their history surgical operations.

Abdominal pain was the presenting complaint in almost all patients (94.87%). In seven patients (17.95%) were seen with peritonitis signs, hypotension and worsening acidosis and were taken to immediately to operating room for exploration. Nausea and vomiting were the second most frequent symptoms (28.20%) , followed by diarrhoea in 9 patients (23.08%). Other symptoms were blood loss for rectum, fever, hematemesis, weight loss and septic signs.

All patients were studied with laboratory tests, x-plain abdomen radiograph, and CT scans. Unfortunately laboratory tests were not homogeneous, in fact lactates were acquired only in 25 patients (64.10%), everyone presented metabolic acidosis and lactate level was elevated. The mean leukocyte count was abnormal, elevated more than $20 \times 10^9/\text{mL}$ in almost 50% of patients. Other elevated laboratory tests were LDH (64.10%), amylase (41.03%), CPK (28.21%), fibrinogen (61.54%), D-dimer (33.33%). X-plain abdomen radiographs were

normal in two cases while the findings, in remaining cases, were nonspecific, like intestinal dilatation and small-bowel obstruction pattern. Computed Tomography scanning was performed in 24 patients (61.54%). Usually it showed nonspecific findings like thickened bowel walls (figure 13), dilated fluid-filled bowel loops (figure 8-10), mesenteric oedema, ascites, calcification of aorta or iliac arteries, infarction of other viscera (figure 12), solid organ ischemia is more common in embolic cases ¹³¹. CT angiography scanning allowed to find superior mesenteric artery obstruction (figure 5), in some cases portal vein thrombosis and superior mesenteric vein thrombosis, in one case portal and splenic vein thrombosis. Our experience with endovascular revascularization is limited in fact angiography was performed in only one patient. It showed the superior mesenteric artery complete obstruction and it was used to start the management through endovascular technique like thrombectomy (figure 14-17). The difficulty to perform angiography in ill patients is due to the place where it is allocated because it is quite far from the emergency operating theatres. Thirty-four patients underwent exploratory laparotomy. In the five remainder patients, two died before arriving to the operating theatre, two refused the operations and one patient was treated only with medical therapy.

In ten laparotomies the intestinal necrosis was massive (figure 1), since it was considered a nonsalvageable condition bowel resection was not performed. It was performed an ileal partial resection in fourteen operations, in five cases an ileal and right colon large resection in two cases right emicolectomy, a resection

of sigma with colostomy, and resection of terminal ileo and transverse colon anastomized in a recent operation of right hemicolectomy. Every operation for acute mesenteric ischemia was by means of laparotomy. Never mesenteric vessels surgical revascularization was performed. The interval from onset of abdominal pain to operation exceeded 24 hours in 28 patients (71.80%). Interval to treatment could not be accurately assessed in one patient because of his dementia. Nobody underwent to second-look procedures.

Significant postoperative morbidity occurred in 22 patients (56.41%). Patients with embolic obstructions had a higher rate of morbidity probably because of the sudden hard appearance of the symptoms and the lack of collateral vessels. Total parental nutrition was required in eight patients during the postoperative period. Major complications, such as cardiorespiratory failure and multiorgan failure (often consequence of septic shock), led to a long Intensive Care Unit staying. Other complications were anaemia in ten patients, with the necessity of blood-transfusions, a case of paroxysmal atrial fibrillation, There were two myocardial infarction and a stroke. Surgical complications were a case of leakage of the an ileo-colic anastomosis, a case of abscesses peri-stomal, a case of a rethrombosis with necrosis of the right colon in a patients operated for small bowel infarction.

Only fourteen patients were discharged and the mean hospital staying was of 15 days. The follow-up of them revealed two death secondary to atherosclerotic coronary disease and one death in a patient with malignancy.

Overall mortality was 64.10%, two cases (5.13%) before the surgical treatment and 23 cases (58.97%) in the perioperative period (30 days). Causes of perioperative mortality included severe cardiorespiratory failure, multyisystem organ failure, suspected or known recurrent bowel ischemia, treated only with supportive care, and cardiac arrests.

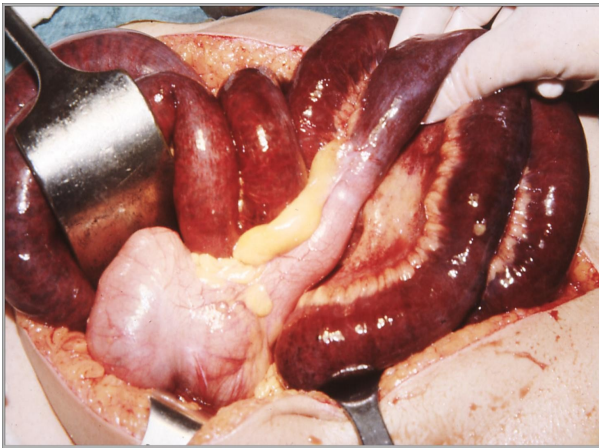


Fig. 1

A large small bowel segment is infarcted and thickened wall.

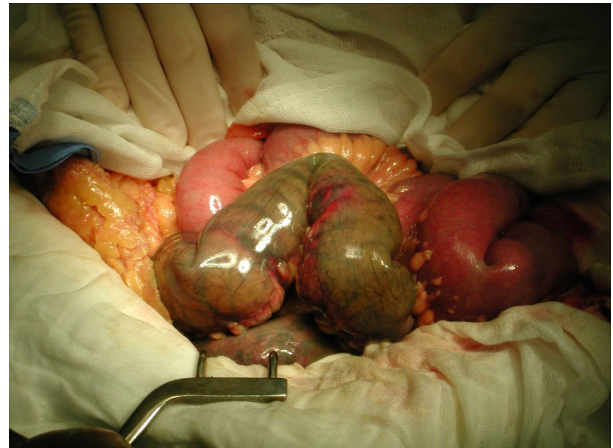

Fig. 2

A limited small bowel segment is infarcted and not thickened wall.

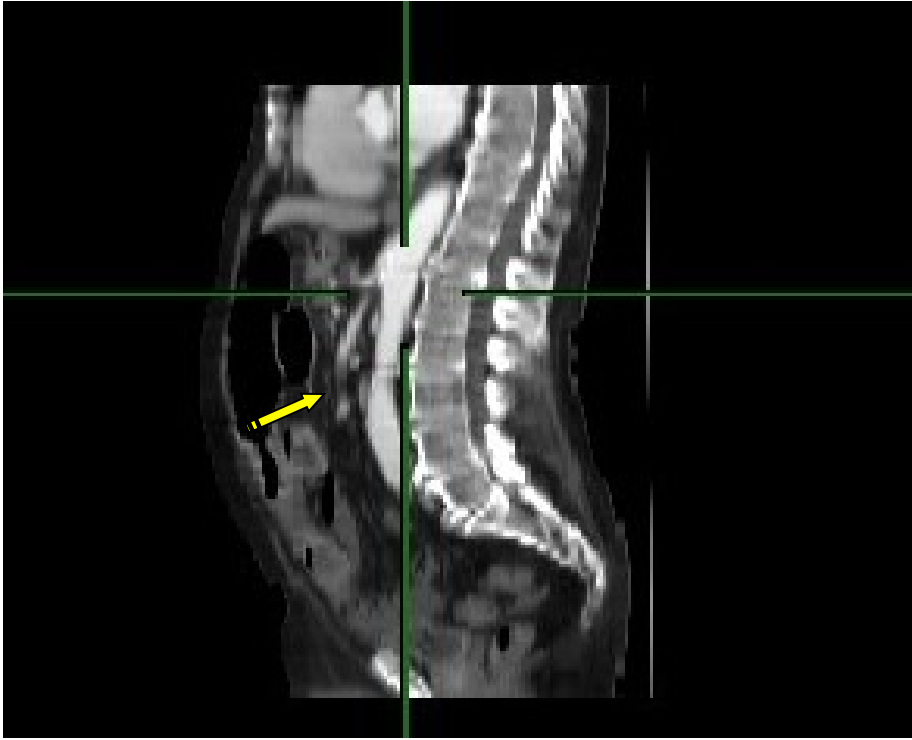


Fig. 3

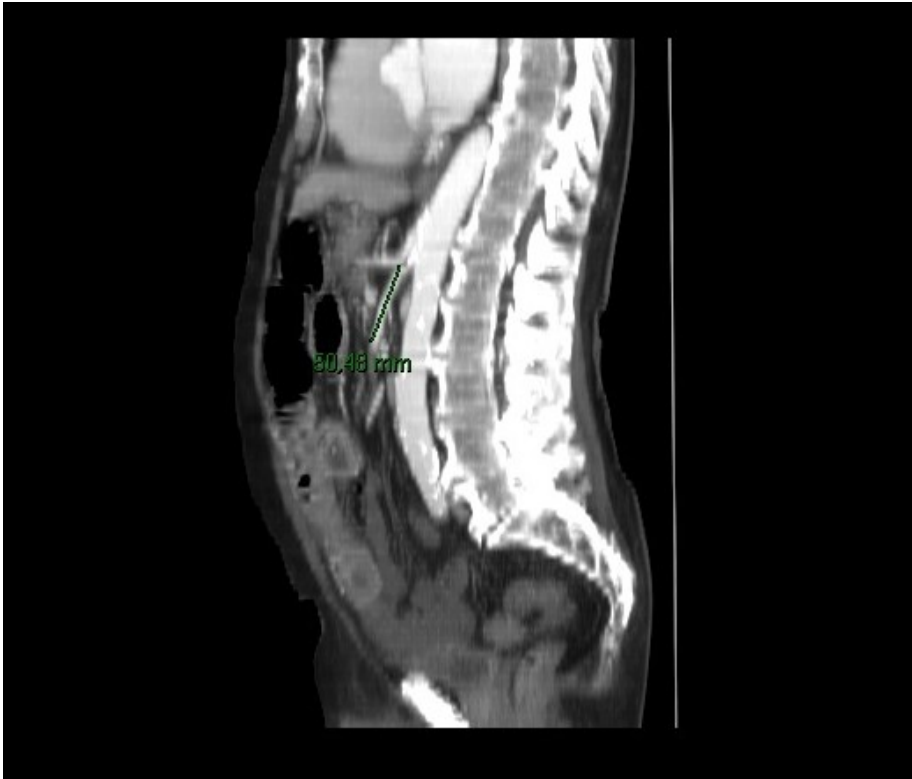


Fig. 4

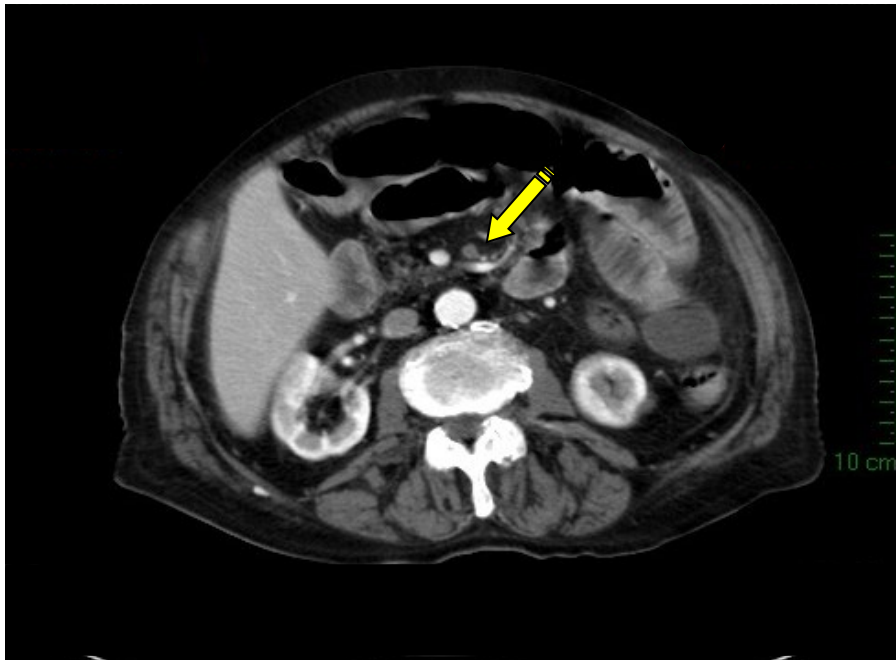


Fig. 5

Fig. 3-5 sagittal MPR and axial contrast-enhanced CT sections in an 85-year-old man with worsening of chronic abdominal pain, especially post-prandial. In these pictures it's possible to note the superior mesenteric artery obstruction about 5 cm distal its origin from aorta. Multiple dilated small bowel loops are evident in the central part of the abdomen. Surgical exploration confirmed segmental bowel ischemia and detectable arterial occlusion.

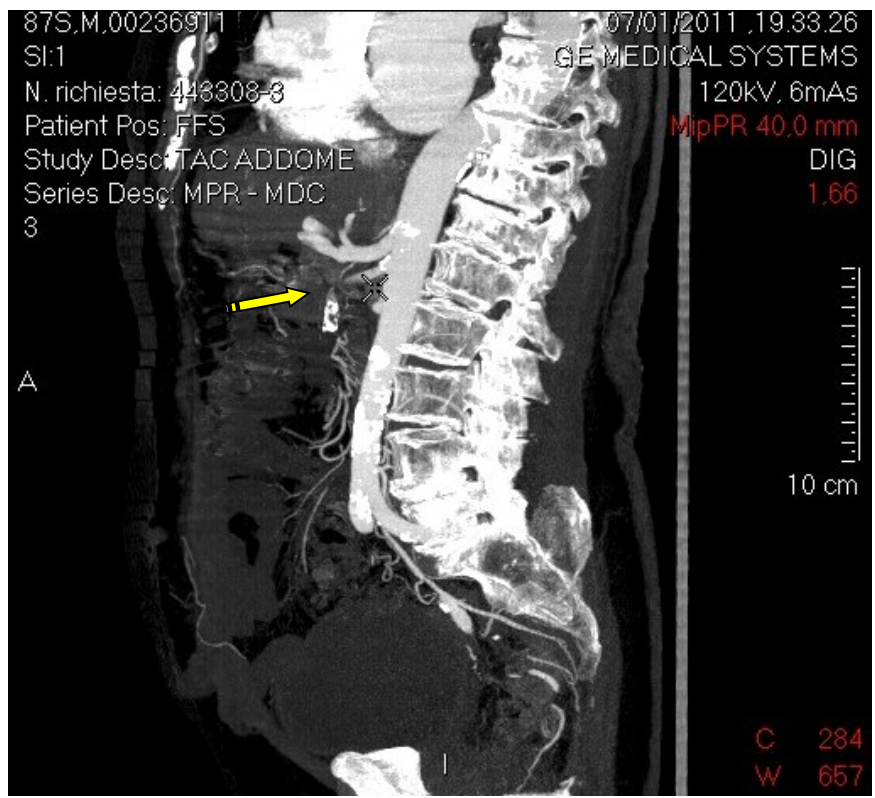


Fig. 6

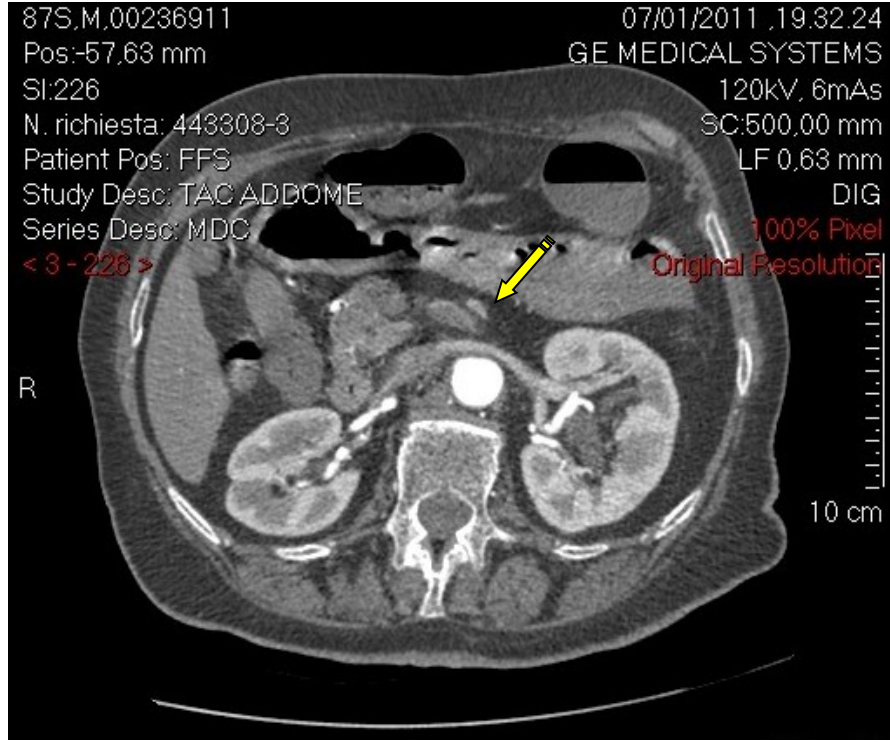


Fig. 7

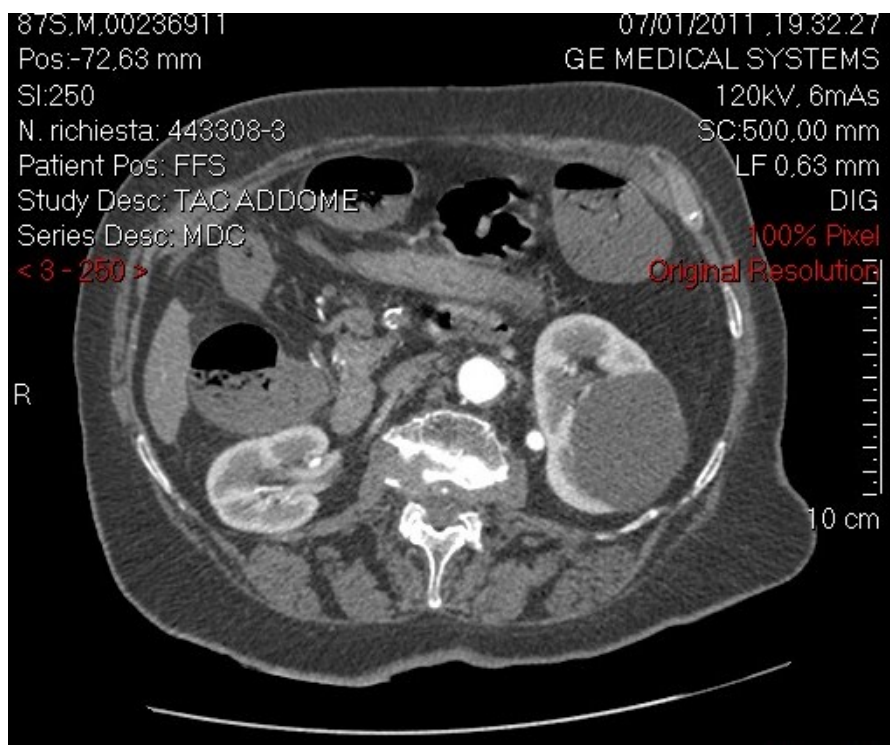


Fig. 8

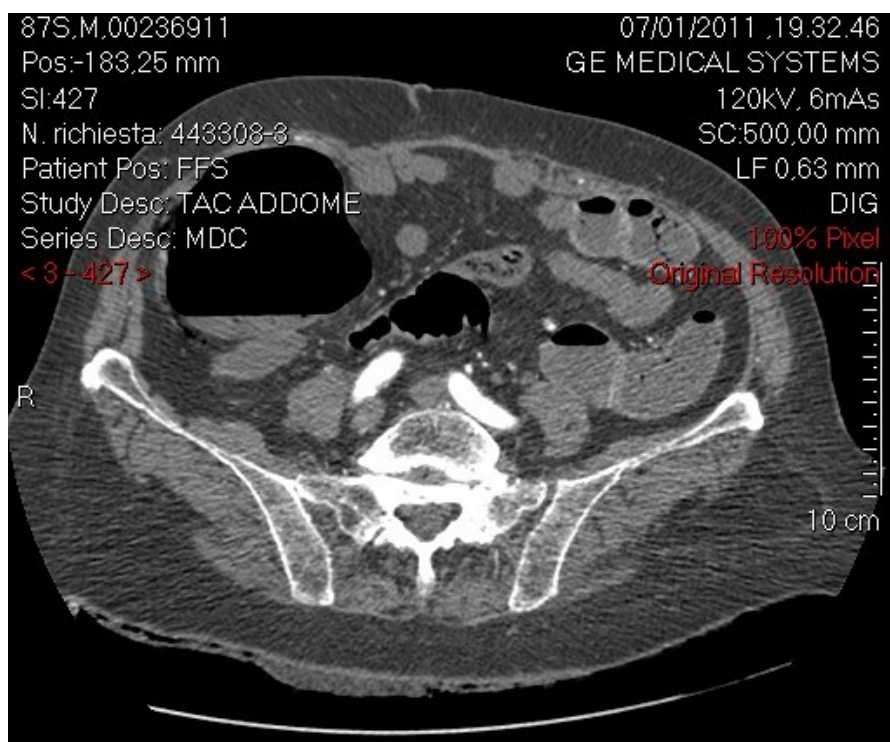


Fig. 9

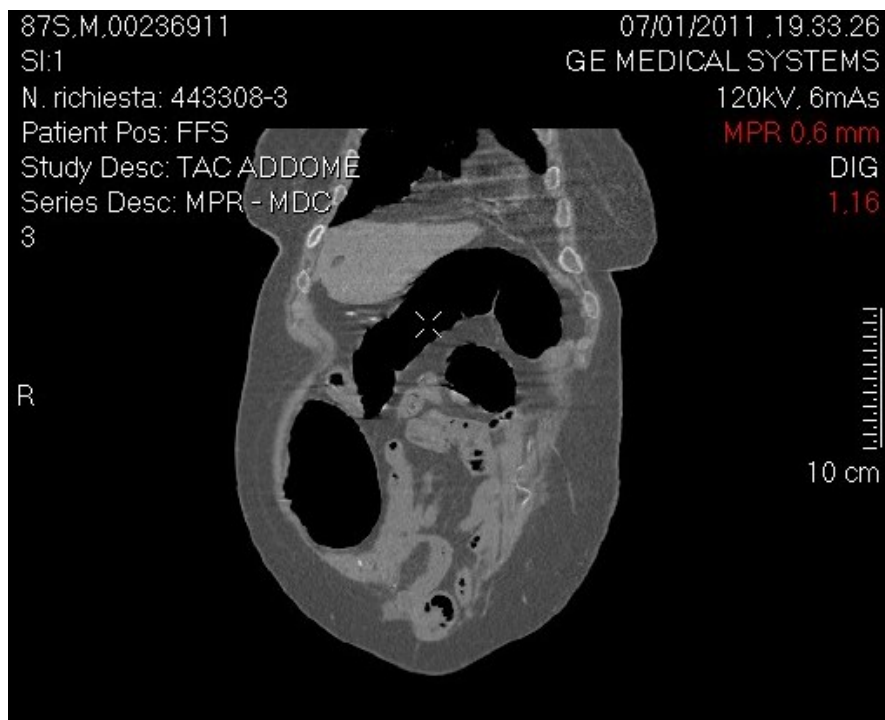


Fig. 10

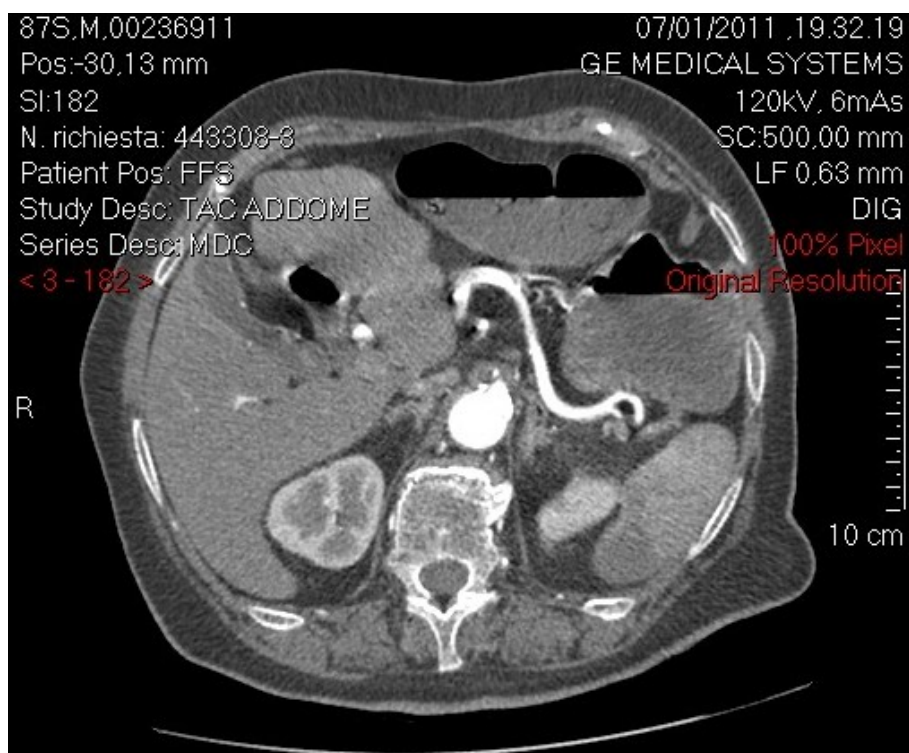


Fig. 11

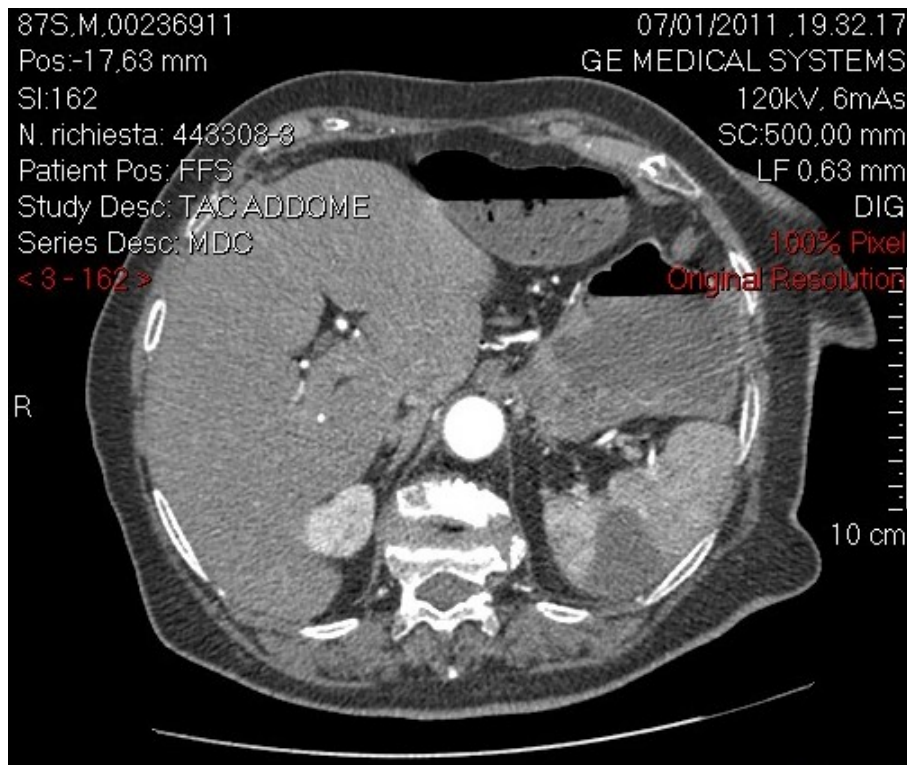


Fig. 12

Fig. 6-12 Sagittal and coronal MPR and axial contrast-enhanced CT angiography slices in a 88-year-old woman with sudden onset of upper and right abdominal pain and recent diagnosis of atrial fibrillation. Patient was not taking anticoagulants, in fact one month before admission she presented sudden embolic cerebrovascular accident. These scans show superior mesenteric occlusion, likely a thromboembolus, multiple dilated and fluid-filled bowel loops (particularly in the right abdomen), right and transverse colonic distension and splenic infarction.

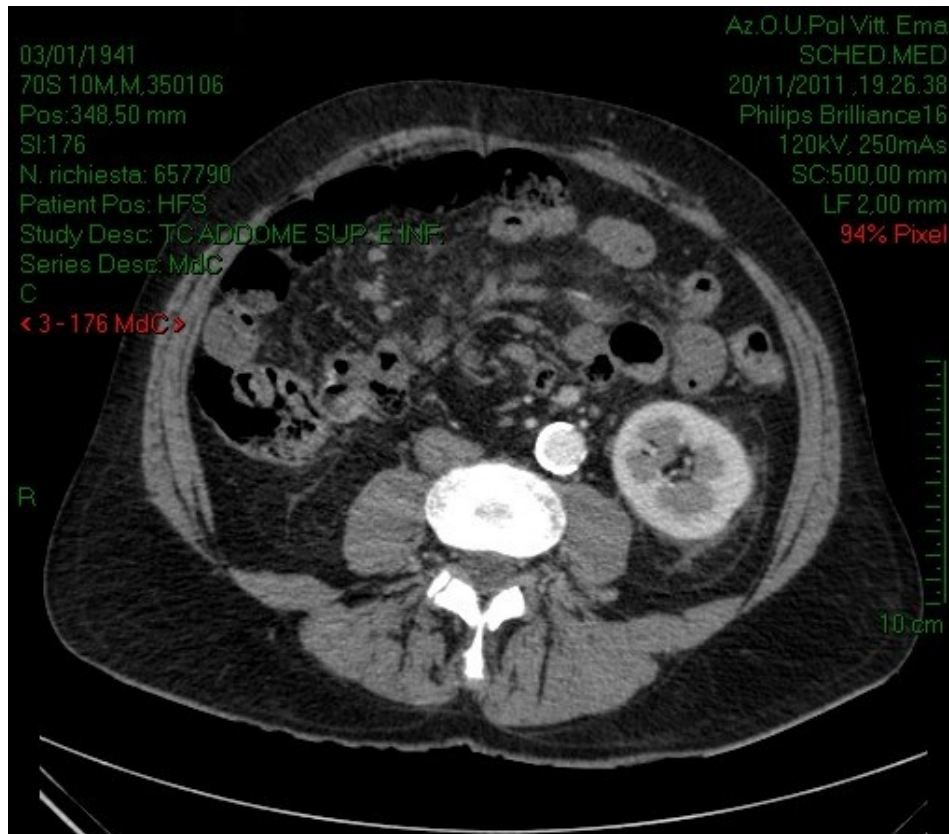


Fig. 13

Fig. 13 Axial contrast enhanced section in a 70-year-old man with sudden upper-central abdominal pain, peripheral vascular disease, hypertension and leucocytosis. Several mildly dilated loops of small bowel are visible. Moreover light bowel wall thickening and reduced enhancement, and mesenteric infiltration are seen while the superior mesenteric artery is not visible. Intraoperatively, 70-cm segment of infarcted small bowel was found without palpable mesenteric pulse.

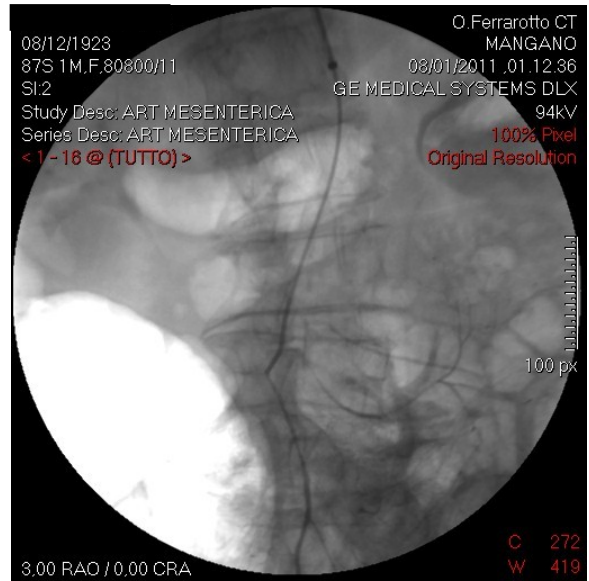
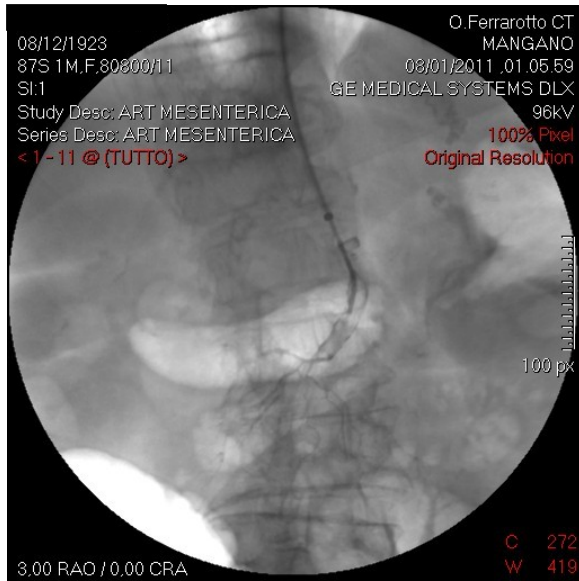


Fig. 14-15

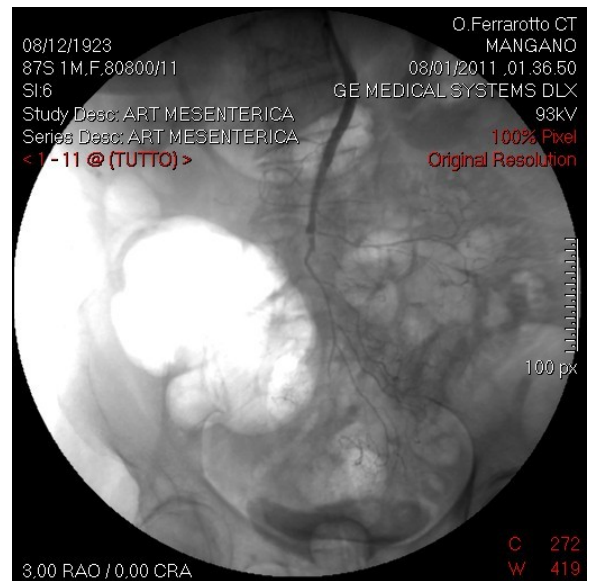
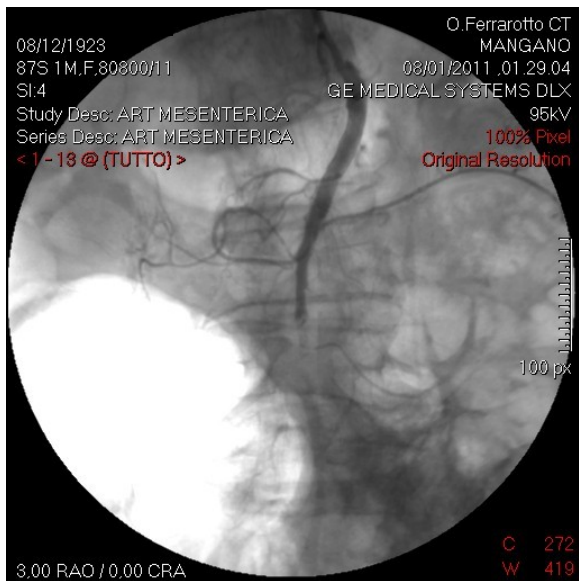


Fig. 16-17

Fig. 14-17 Sequence of arteriography in a 88-year-old woman performed using left brachial access. This patient was treated by trombectomy but the surgical exploration was not performed since she died before operation.

CONCLUSION

Acute mesenteric ischemia is not a solitary clinical entity but rather a complex of disease with many clinical characteristics caused by hypoperfusion of the bowel. Our retrospective review confirms acute mesenteric ischemia presents many predisposing factors like old aging, atherosclerosis, hypercoagulability or cardiac arrhythmias not correctly treated. This disease remains a highly lethal clinical entity. It's necessary to maintain a high index of suspicion in abdominal pain in elderly to can lead to an early diagnosis. Actually it is no so simple and commonly patients tend to present late when intestinal necrosis is already advanced. It may be considered a predictor of adverse outcome, in fact a small proportion of patients survives massive bowel resection and develops short-gut syndrome, requiring long-term total parental nutrition. Occlusive or nonocclusive mesenteric ischemia has different features, outcome, and treatment options, therefore vessels anatomy assessment and accurate tests are crucial. The physician has to decide from the often enough contradictory information of prodromic symptoms, physical examination, laboratory findings and noninvasive imaging procedures if he wants to proceed to invasive tests to exclude or to confirm mesenteric ischemia. The rapid development of CT angiography in case of abdominal syndromes has led to more frequent and also earlier diagnosis of bowel ischemia, moreover the development of new endovascular techniques has led to improved outcome. There are different treatment options, including noninvasive, minimal invasive and classical open vascular reconstructive techniques, and the

choice depends from a multi-disciplinary team approach, since to apply the most proper management and to improve the prognosis.

REFERENCES

1. Lock G. Acute intestinal ischemia. *Best Pract Res Clin Gastroenterol* 2001; 15: 83-98
2. Mansour MA. Management of acute mesenteric ischemia. *Arch Surg* 1999; 134: 328-330, discussion 31
3. Ottinger LW. The surgical management of acute occlusion of the superior mesenteric artery. *Ann Surg* 1978; 188: 721-731
4. Wilson C, Gupta R, Gilmour DG, et al. Acute superior mesenteric ischaemia. *Br J Surg* 1987; 74: 279-281
5. Boley SJ, Feinstein FR, Sammartano R, et al. New concepts in the management of emboli of the superior mesenteric artery. *Surg Gynecol Obstet* 1981; 153: 561-569
6. Hertzner NR, Beven EG, Humphries AW. Acute intestinal ischemia. *Am Surg* 1978; 44: 744-749
7. Batellier J, Kieny R. Superior mesenteric artery embolism: eighty-two cases. *Ann Vasc Surg* 1990; 4: 112-116
8. Lazaro T, Sierra L, Gesto R, et al. Embolization of the mesenteric arteries: surgical treatment in twenty-three consecutive cases. *Ann Vasc Surg* 1986; 1: 311-315
9. Benjamin E, Oropello JM, Iberti TJ. Acute mesenteric ischemia: pathophysiology, diagnosis, and treatment. *Dis Mon* 1993; 39: 131-210
10. Bradbury AW, Brittenden J, McBride K, et al. Mesenteric ischaemia: a multidisciplinary approach. *Br J Surg* 1995; 82: 1446-1459

11. Bruch HP, Broll R, Wunsch P, et al. Non-occlusive ischemia enteropathy: diagnosis, therapy and prognosis. *Chirurg* 1989; 60: 419-425
12. Ottinger L, Austen WB. A study of 136 patients with mesenteric infarction. *Surg Gynecol Obstet* 1967; 124: 251-261
13. Singh RP, Shah RC, Lee ST. Acute mesenteric vascular occlusion: a review of thirty-two patients. *Surgery* 1975; 78: 613-617
14. Smith S, Patterson LT. Acute mesenteric infarction. *Am J Surg* 1976; 42: 562-567
15. Boley SJ, Sprayregen S, Siegelman SS, et al. Initial results from an aggressive roentgenological and surgical approach to acute mesenteric ischemia. *Surgery* 1977; 848-855
16. Kairaluoma MI, Karkola P, Heikkinen D, et al. Mesenteric infarction. *Am J Surg* 1977; 133: 188-193
17. Krausz MM, Manny J. Acute superior mesenteric arterial occlusion: a plea for early diagnosis. *Surgery* 1977; 82: 856-866
18. Sachs SM, Morton JH, Schwartz SI. Acute mesenteric ischemia. *Surgery* 1982; 92: 646-653
19. Andersson R, Parson H, Isaksson B, et al. Acute intestinal ischemia: a 14 year retrospective investigation. *Acta Chir Scand* 1984; 150: 217-221
20. Sitges-Serra A, Mas X, Roqueta F, et al. Mesenteric infarction: an analysis of 83 patients with prognostic studies in 44 cases undergoing massive small-bowel resection. *Br J Surg* 1988; 75: 544-548

21. Finucane PM, Arunachalam T, O'Dowd J, et al. Acute mesenteric infarction in elderly patients. *J Am Geriatr Soc* 1989; 37: 355-358
22. Bapat RD, Aiyer PM, Relekar RG, et al. Ischemic bowel disease. *Indian J Gastroenterol* 1990; 9: 19-22
23. Levy PJ, Krausz MM, Manny J. Acute mesenteric ischemia: improved results – a retrospective analysis of ninety-two patients. *Surgery* 1990; 107: 372-380
24. Deehan DJ, Heys SD, Brittenden J, et al. Mesenteric ischaemia: prognostic factors and influence of delay upon outcome. *J Royal Coll Surg Edinburgh* 1995; 40: 112-115
25. Ward D, Vernava AM, Kaminski DL, et al. Improved outcome by identification of high-risk non-occlusive mesenteric ischemia, aggressive reexploration, and delayed anastomosis. *Am J Surg* 1995; 170: 577-581
26. Konturek A, Cichon S, Gucwa J, et al. Acute intestinal ischemia in material of the III Clinic of General Surgery, Collegium Medicum at the Jagellonian University. *Przegl Lek* 1996; 53: 719-721
27. Voltolini F, Pricolo R, Naldini G, et al. Acute mesenteric ischemia. Analysis of 47 cases. *Miner Chir* 1996; 51: 285-292
28. Kempnauer J, Grothues F, Bektas H, et al. Long-term results after surgery for acute mesenteric ischemia. *Surgery* 1997; 121: 239-243
29. Urayama H, Ojtake H, Kawakama T, et al. Acute mesenteric vascular occlusion: analysis of 39 patients. *Eur J Surg* 1998; 164: 195-200

30. Newman TS, Maguson TH, Ahrendt SA, et al. The changing face of mesenteric infarction. *Am Surg* 1998; 64: 611-616
31. Mamode N, Pickford I, Leiberman P. Failure to improve outcome in acute mesenteric ischaemia: seven year review. *Eur J Surg* 1999; 165: 203-208
32. Foley MI, Moneta GL, Abou-Zamzam AM, et al. Revascularization of the superior mesenteric artery alone for treatment of intestinal ischemia. *J Vasc Surg* 2000; 32: 37-47
33. Park WM, Gloviczki P, Cherry KJ, et al. Contemporary management of acute mesenteric ischemia: factors associated with survival. *J Vasc Surg* 2002; 35(3): 445-452
34. Edwards MS, Cherr GS, Craven TE, et al. Acute occlusive mesenteric ischemia: surgical management and outcomes. *Ann Vasc Surg* 2003; 17(1): 72-79
35. Wyers MC, Powell RJ, Nolan BW, et al. Retrograde mesenteric stenting during laparotomy for acute occlusive mesenteric ischemia. *J Vasc Surg* 2007; 45(2): 269-275
36. Kassahun WT, Schulz T, Richter O, et al. Unchanged high mortality rates from acute occlusive intestinal ischemia: six year review. *Langenbecks Arch Surg* 2008; 393: 163-171
37. Bjork M, Troeng T, Bergqvist D. Risk factors of intestinal ischaemia after aortoiliac surgery: a combined cohort and case-control study of 2824 operations. *Eur J Vas Endovasc Surg* 1997; 13: 531-539

38. Roobottom CA, Dubbins PA. Significant disease of the celiac and superior mesenteric arteries in asymptomatic patients: predictive value of Doppler sonography. *Am J Roentgenol* 1993; 161: 985-988
39. Brandt LJ, Boley SJ. AGA technical review on intestinal ischemia. *Gastroenterology* 2000; 118: 954-968
40. Berland T, Oldenburg WA. Acute mesenteric ischemia. *Current Gastroenterol reports* 2008; 10: 341-346
41. Fuster V, Ryden LE, Asinger RW, et al. ACC/AHA/ESC Guidelines for the Management of Patients with Atrial Fibrillation: Executive Summary a Report of the America College of Cardiology/American Heart Association Task Force on Practice Guidelines and the European Society of Cardiology Committee for Practice Guidelines and Policy Conferences (Committee to develop Guidelines for the Management of patients with Atrial Fibrillation) Developed in collaboration with the Nord American Society of Pacing and Electrophysiology. *Circulation* 2001; 104: 2118-2150
42. Bron KM, Redman HC. Splanchnic artery stenosis and occlusion. Incidence, arteriographic and clinical manifestations. *Radiology* 1969; 92: 323-328
43. Stoney RJ, Cunningham CG. Acute mesenteric ischemia. *Surgery* 1993; 114: 489-490
44. Li KC, Hopkins KL, Dalman RL, et al. Simultaneous measurement of flow in the superior mesenteric vein and artery with cine phase-contrast MR

imaging: Value in diagnosis of chronic mesenteric ischemia. Work in progress. *Radiology* 1995; 194: 327-330

45. Acosta S. Epidemiology of mesenteric vascular disease: clinical implications. *Sem Vasc Surg* 2010; 23: 4-8
46. Rhee RY, Gloviczki P, Mendonca CT, et al. Mesenteric venous thrombosis: still a lethal disease in the 1990s. *J Vasc Surg* 1994; 20: 688-697
47. Wilcox MG, Howard TJ, Plaskon LA, et al. Current theories of pathogenesis and treatment of nonocclusive mesenteric ischemia. *Dig Dis Sci* 1995; 40: 709-716
48. Howard TJ, Plaskon LA, Wiebke EA, et al. Nonocclusive mesenteric ischemia remains a diagnostic dilemma. *Am J Surg* 1996; 171: 405-408
49. Acosta S, Ogren M, Sternby N-H, et al. Fatal nonocclusive mesenteric ischemia: population-based incidence and risk factors. *J intern Med* 2006; 259: 305-313
50. Mikkelsen E, Andersson KE, Pedersen OL. Effects of dogoxin on isolated human mesenteric vessels. *Acta Pharmacol Toxicol* 1979; 45: 25-31
51. Lock G, Scholmerich J. Non-occlusive mesenteric ischemia. *Hepato-Gastroenterology* 1995; 42: 234-239
52. Sudhakar CBS, Al-Hakeem M, MacArthur Jd, et al. Mesenteric ischemia secondary to cocaine abuse: case reports and literature review. *Am J Gastroenterol* 1997; 92: 1053-1054

53. Vicente DC, Kazmers A. Acute mesenteric ischemia. *Cur Opin Cardiol* 1999; 14: 453-463
54. Wyers MC, Zwolack RM. The management of splanchnic vascular disorders. In *Vascular Surgery*, edn 6. Philadelphia: Rutheford-Elsevier-Saunders; 2005: 1707-1717
55. Oldenburg WA, Lau LL, Rodenberg TJ, et al. Acute mesenteric ischemia. *Arch Int Med* 2004; 164: 1054-1062
56. Roseblum JD, Boyle CM, Schwartz LB. The mesenteric circulation. Anatomy and physiology. *Surg Clin North Am* 1997; 77: 289-306
57. Yasuhara H. Acute mesenteric ischemia: the challenge of gastroenterology. *Surg Today* 2005; 35: 185-195
58. Bergan JJ, Yao JST. Chronic intestinal ischemia. In *Vascular Surgery*, edn 3. Philadelphia: Rutheford- Saunders; 1989: 825-842
59. Kolkman JJ, Groeneveld AB. Occlusive and non-occlusive gastrointestinal ischemia: A clinical review with special emphasis on the diagnostic value of tonometry. *Scand J Gastroenterol Suppl* 1998; 225: 3-12
60. Kurland B, Brandt LJ, Delany HM. Diagnostic tests for intestinal ischemia. *Surg Clin North Am* 1992; 72: 85-105
61. Block T, Nilsson TK, Bjork M, et al. Diagnostic accuracy of plasma biomarkers for intestinal ischemia. *Scand J Clin Lab Invest* 2008; 68: 242-248

62. El-Awady SI, El-Nagar M, El-Dakar M, et al. Bacterial trans location in an experimental intestinal obstruction model. C-reactive protein reliability? *Acta Cir Bras* 2009; 24: 98-106
63. Kurimoto Y, Kawarahada N, Ito T, et al. An experimental evaluation of the lactate concentration following mesenteric ischemia. *Surg Today* 2008; 38: 926-930
64. May LD, Berenson MM. Value of of serum inorganic phosphate in the diagnosis of ischemic bowel disease. *Am J Surg* 1983; 146: 266-268
65. Acosta S, Nilsson TK, Bjork M. Preliminary study of D-dimer as a possible marker of acute bowel ischaemia. *Br J Surg* 2001; 88: 385-388
66. Acosta S, Nilsson TK, Bjork M. D-dimer testing in patients with suspected acute thromboembolic occlusion of the superior mesenteric artery. *Br J Surg* 2004; 91: 991-994
67. Altinyollar H, Boyabatli M, Berberoglu U. D-dimer as a marker for early diagnosis of acute mesenteric ischemia. *Thromb Res* 2006; 117: 463-467
68. Vaan Nord D, Mensink PBF, De Knecht RJ, et al. Serum markers and intestinal mucosal injury in chronic gastrointestinal ischemia. *Dig Dis Sci* 2011; 56: 506-512
69. Kanda T, Fujii H, Tani T, et al. Intestinal fatty acid-binding protein is a useful diagnostic marker for mesenteric infarction in humans. *Gastroenterology* 1996; 110. 339-343

70. Smerud MJ, Johnson JD, Stephens DH. Diagnosis of bowel infarction: a comparison of plain films and CT scans in 23 cases. *Am J Roentgenol* 1990; 154: 99-103
71. Kolkman JJ, Bargeman M, Huisman AdB, et al. Diagnosis and management of splanchnic ischemia. *World J Gastroenterol* 2008; 14 (48): 7309-7320
72. Cappell MS. Intestinal (mesenteric) vasculopathy I. Acute superior mesenteric arteriopathy and venopathy. *Gastroenterol Clin North Am* 1998; 27: 783-825
73. Kernagis LY, Levine MS, Jacobs JE. Pneumatosis intestinalis in patients with ischemia: correlation of CT findings with viability of bowel. *Am J Roentgenol* 2003; 180: 733-736
74. Rhee RY, Gloviczki P. Mesenteric venous thrombosis. *Surg Clin North Am* 1997; 77: 327-338
75. Vogelzang RL, Gore RM, Anschnetz SL, et al. Thrombosis of the splanchnic veins: CT diagnoses. *Am J Roentgenol* 1988; 150: 93-96
76. Harward TR, Green D, Bergan JJ, et al. Mesenteric venous thrombosis. *J Vasc Surg* 1989; 9: 328-333
77. Rahmouni A, Mathieu D, Golli M, et al. Value of CT and sonography in the conservative management of acute splenorenal and superior mesenteric venous thrombosis. *Gastrointestinal Radiology* 1992; 17: 135-140
78. Desai SR, Cox MR, Martin CJ. Superior mesenteric vein thrombosis: computed tomography diagnosis. *Aust N Z J Surg* 1998; 68: 811-812

79. Laghi A, Iannaccone R, Catalano C, et al. Multislice spiral computed tomography angiography of mesenteric arteries. *Lancet* 2001; 358: 638-639
80. Iannaccone R, Laghi A, Passariello R. Multislice CT angiography of mesenteric vessels. *Abdom Imaging* 2004; 29: 146- 152
81. Horton KM, Fishman EK. Multidetector CT angiography in the diagnosis of mesenteric ischemia. *Radiol Clin North Am* 2007; 45: 275-288
82. Savastano S, Teso S, Corra S, et al. Multislice CT angiography of the celiac and superior mesenteric arteries: comparison with arteriographic findings. *Radiol Med* 2002, 103: 456-463
83. Ilica AT, Kocaoglu M, Bilici A, et al. Median arcuate ligament syndrome: multidetector computed tomography findings. *J Comput Assist Tomogr* 2007; 31: 728-731
84. Wyers MC. Acute mesenteric ischemia: diagnostic approach and surgical treatment. *Semin Vasc Surg* 2010; 23: 9-20
85. Stueckle CA, Haegele KF, Jendrek M, et al. Multislice computed tomography angiography of the abdominal arteries: comparison between computed tomography angiography and digital subtraction angiography findings in 52 cases. *Australas Radiol* 2004; 48: 142-147
86. Laghi A, Catalano C, Iannaccone R, et al. Multislice spiral CT angiography in the evaluation of the anatomy of splanchnic vessels: preliminary experience. *Radiol Med* 2001; 102: 127-131

- 87.**Aschoff AJ, StuberG, Becker BW, et al. Evaluation of acute mesenteric ischemia: accuracy of biphasic mesenteric multi-detector CT angiography. *Abdom Imaging* 2009; 34: 345-357
- 88.**Klein HM, Klosterhalfen B, Kinzel S, et al. CT and MRI of experimentally induced mesenteric ischemia in porcine model. *J Comput Assist Tomogr* 1996; 20: 254-261
- 89.**Meaney JF, Prince MR, Nostrant TT, et al. Gadolinium-enhanced MR angiography of visceral arteries in patients with suspected chronic mesenteric ischemia. *J Magn Reson Imaging* 1997; 7: 171-176
- 90.**Hagspiel KD, Leung DA, Angle JF, et al. MR angiography of the mesenteric vasculature . *Radiol Clin North Am* 2002; 40: 867-886
- 91.**Bradbury MS, Kavanagh PV, Chen MY, et al. Noninvasive assessment of portomesenteric venous thrombosis: current concepts and imaging strategies. *J Comput Assist Tomogr* 2002; 26: 392-404
- 92.**Schneider TA, Longo WE, Ure T, et al. Mesenteric ischemia: acute arterial syndromes. *Dis Colon Rectum* 1994; 37: 1163-1174
- 93.**Clavien PA. Diagnosis and management of mesenteric infarction. *Br J Surg* 1990; 77: 601-603
- 94.**Clark RA, Gallant TE. Acute mesenteric ischemia: angiographic spectrum. *Am J Radiol* 1984; 142: 555-562
- 95.**Aakhus T, Evenson A. Angiography in acute mesenteric insufficiency. *Acta Radiol Diag* 1978; 19: 945-954

96. Abdu RA, Zakhour BJ, Dallis DJ. Mesenteric venous thrombosis: 1911 to 1984. *Surgery* 1987; 101: 383-388
97. Grace Pa, DaCosta M, Qureshi A, et al. An aggressive approach to acute mesenteric arterial ischemia. *Eur J Vasc Surg* 1993; 7: 731-732
98. Gewertz BL; Baldwin ZK. Acute mesenteric ischemia. In *Current Surgical Therapy*, edn 8, Philadelphia: Elsevier Mosby; 2004: 846-849
99. Kolkman JJ, Mensink PB, van Petersen AS, et al. Clinical approach to chronic gastrointestinal ischaemia: from 'intestinal angina' to the spectrum of chronic splanchnic disease. *Scand J Gastroenterol Suppl* 2004; 9-16
100. Bakal CW, Sprayregen S, Wolf EL. Radiology in intestinal ischemia. Angiographic diagnosis and management. *Surg Clin North Am* 1992; 72: 125-141
101. Siegelman SS, Sprayregen S, Boley SJ. Angiographic diagnosis of mesenteric arterial vasoconstriction. *Radiology* 1974; 122: 533-542
102. Meilahn JE, Morris JB, Ceppa EB, et al. Effect of prolonged selective intramesenteric arterial vasodilator therapy on intestinal viability after acute segmental mesenteric vascular occlusion. *Ann Surg* 2001; 234: 107-115
103. Savassi-Rocha PR, Veloso LF. Treatment of superior mesenteric artery embolism with a fibrinolytic agent: case report and literature review. *Hepatogastroenterology* 2002; 49: 1307-1310

104. Brountzos EN, Critselis A, Magoulas D, et al. Emergency endovascular treatment of a superior mesenteric artery occlusion. *Cardiovasc Intervent Radiol* 2001; 24: 57-60
105. Resch TA, Acosta S, Sonesson B. Endovascular techniques in acute arterial mesenteric ischemia. *Sem Vasc Surg* 2010, 23: 29-35
106. Bracht H, Takala J, Tenhunen JJ, et al. Hepatosplanchnic blood flow control and pxygen extraction are modified by the underlying mechanism of impaired perfusion. *Crit Care Med* 2005; 33: 645-653
107. Jakob SM, Tenhunen JJ, Heino A, et al. Splanchnic vasoregulation during mesenteric ischemia nd reperfusion in pigs. *Shock* 2002; 18: 142-147
108. Jakob SM, Merasto-Minkkinen M, Tenhunen JJ, et al. Prevention of systemic hyperlactatemia during splanchnic ischemia. *Shock* 2000; 14: 123-127
109. Lautt WW. Regulatory processes interacting to maintain hepatic blood flow constancy: vascular compliance, hepatic arterial buffer response, hepatorenal reflex, liver regeneration, escape from vasoconstriction. *Hepatol Res* 2007; 37: 891-903
110. Kudomi N, Slimani L, Jarvisalo MJ, et al. Non-invasive estimation of hepatic blood perfusion from H(2) (15)O PET images using tissue-derived arterial and portal input functions. *Eur J Nucl Med Mol Imaging* 2008; 35: 1899-1911

111. Iozzo P, Jarvisalo MJ, Kiss J, et al. Quantification of liver glucose metabolism by positron emission tomography: validation study in pigs. *Gastroenterology* 2007; 132: 531-542
112. Kiss J, Naum A, Kudomi N, et al. Non-invasive diagnosis of acute mesenteric ischaemia using PET. *Eur J Nucl Med Mol Imaging* 2009; 36: 1338-1345
113. Sarelund S, Agresta F, Bergamaschi R, et al. Laparoscopy for abdominal emergencies: Evidenced-based guidelines of the European Association for Endoscopic Surgery. *Surg Endosc* 2006; 20: 14-29
114. Rhee RY, Gloviczki P, Mendonca CT, et al. Mesenteric venous thrombosis: still a lethal disease in the 1990s. *J Vasc Surg* 1994; 20: 688-697
115. Demirpolat G, Oran I, Tamsel S, et al. Acute mesenteric ischemia: endovascular therapy. *Abdom Imaging* 2007; 32: 299-30
116. Sonesson B, Hinchliffe RJ, Dias NV, et al. Hybrid recanalization of superior mesenteric artery occlusion in acute mesenteric ischemia. *J Endovasc Ther* 2008; 15: 129-132
117. Moyes LH, McCarter DH, Vass DG, et al. Intraoperative retrograde mesenteric angioplasty for acute occlusive mesenteric ischemia: a case series. *Eur J Vasc Endovasc Surg* 2008; 36: 203-206

118. Milner R, Woo EY, Carpenter JP. Superior mesenteric artery angioplasty and stenting via a retrograde approach in a patient with bowel ischemia – a case report. *Vasc Endovasc Surg* 2004; 38: 89-91
119. Brown DJ, Schermerhorn ML, Powell RJ, et al. Mesenteric stenting for chronic mesenteric ischemia. *J Vasc Surg* 2005; 42: 268-274
120. Silva JA, White CJ, Collins TJ, et al. Endovascular therapy for chronic mesenteric ischemia. *J Am Coll Cardiol* 2006; 47: 944-950
121. Kasirajan K, O'Hara PJ, Gray BH, et al. Chronic mesenteric ischemia: open surgery versus percutaneous angioplasty and stenting. *J Vasc Surg* 2001; 33: 63-71
122. Landis MS, Rajan DK, Simons ME, et al. Percutaneous management of chronic mesenteric ischemia: outcomes after intervention. *J Vasc Interv Radiol* 2005; 16: 1319-1325
123. Shanley CJ, Ozaki K, Zelenok GB. Bypass grafting for chronic mesenteric ischemia. *Surg Clin North Am* 1997; 77: 381-395
124. Carter MS, Fantini GA, Sammartano RJ, et al. Qualitative and quantitative fluorescein fluorescence in determining intestinal viability. *Am J Surg* 1984; 147: 117-123
125. Redaelli CA, Schilling MK, Carrel TP. Intraoperative assessment of intestinal viability by laser Doppler flowmetry for surgery of ruptured abdominal aortic aneurysms. *World J Surg* 1998; 22: 283-289

126. Endean ED, Barnes SL, Kwolek CJ, et al. Surgical management of thrombotic acute intestinal ischemia. *Ann Surg* 2001; 233: 801-808
127. Kougias P, Lau D, El Sayed HF, et al. Determinants of mortality and treatment outcome following surgical interventions for acute mesenteric ischemia. *J Vasc Surg* 2007; 46: 467-474
128. Tola M, portoghese A, Maniga AM. Laparoscopic second-look in acute intestinal ischemia. *Minerv Chir* 1997; 52: 527-530
129. Seshandri PA, Poulin EC, Mamazza J, et al. Simplified laparoscopic approach to “second-look” laparotomy: a review. *Surg Laparosc Endosc Percutan Tech* 1999; 9: 286-289
130. Dunn MM, McFall TA, Rgano WD, et al. Adjunctive vasodilator therapy in the treatment of murine ischemia. *Am J Surg* 1993; 165: 697-699
131. Barajas RF, Yeh BM, Webb EM, et al. Spectrum of CT findings I patients with atrial fibrillation and nontraumatic acute abdomen. *Am J Roentgenol* 2009; 193: 485-492